



PATIENT

Ragnar Hitchcock

PRESENTING CLINICAL SIGNS

Clinical Exam Findings: Exam unremarkable
Abnormal lab-work values: Recent BW unremarkable

SPECIES

Canine

BREED

Cairn Terrier

ULTRASONOGRAPHIC EXAMINATION OF THE ABDOMEN

Urinary System

The urinary bladder wall is normal in thickness and the mucosal surface is smooth. The bladder is distended. A small amount of suspended echogenic debris is observed within the lumen. No masses, inflammatory changes or calculi are observed. Ureteral papillae and visualized portion of the proximal urethra, visible to a depth of 2-3 cm, are normal.

SEX

Neutered Male

The prostate is normal in size (0.60 cm in width) and shape. Parenchyma is homogenous. The prostatic urethra appears normal without evidence of dilation or obstruction.

AGE

11/27/2016

The left kidney is normal in size (4.64 cm in length) with a normal shape, architecture and smooth peripheral margins. There is a normal 1:3 cortex to medulla ratio with normal corticomedullary distinction. A faint hyperechoic medullary band is observed at the corticomedullary junction. There is no evidence of pyelectasia, nephroliths, infarcts or hydroureter. Renal vasculature is normal.

The right kidney is normal in size (4.78 cm in length) with a normal shape, architecture and smooth peripheral margins. There is a normal 1:3 cortex to medulla ratio with normal corticomedullary distinction. A faint hyperechoic medullary band is observed at the corticomedullary junction. There is no evidence of pyelectasia, nephroliths, infarcts or hydroureter. Renal vasculature is normal.

WEIGHT

19.4 lbs

Adrenal Glands

The left adrenal gland is normal in size (0.30 cm at cranial pole) (0.39 cm at caudal pole) with a normal shape and homogenous parenchyma. The glandular echogenicity and detail are unremarkable. Capsule, cortex, and medullary definition are normal. The phrenicoabdominal vein and surrounding vasculature are normal.

The right adrenal gland is in normal size (0.83 cm at cranial pole) (0.52 cm at caudal pole) with a normal shape and homogenous parenchyma. The glandular echogenicity and detail are unremarkable. Capsule, cortex, and medullary definition are normal. The phrenicoabdominal vein and surrounding vasculature are normal.

INTERPRETED BY

Andrea Nicastro, DVM,
Diplomate ACVIM (*Small
Animal Internal Medicine*)

IMAGING PERFORMED BY

Andrea Nicastro, DVM,
Diplomate ACVIM (*Small
Animal Internal Medicine*)

Spleen

The spleen is normal in size (1.11 cm in width at the level of the hilus) with a normal capsular contour. The parenchyma is subtly mottled in appearance. No focal lesions are observed. Splenic vasculature is normal.

HOSPITAL NAME

Kevin Moser

Liver

The liver is subjectively normal in size with normal contours and structure. There is appropriate echogenicity and echotexture. No overt structural evidence of inflammatory, infiltrative, or regenerative pathology is evident. Vascular and biliary tracts are of normal volume with no evidence of congestion. No pathological hepatic lymphadenopathy observed. The portal vein to caudal vena cava ratio is approximately 1: 1.

REFERRING VET

Southside AH

The gall bladder lumen is moderately distended. The wall is thin and smooth. A small amount of suspended echogenic debris is observed within the lumen. The cystic and common bile ducts are normal/not seen.

INVOICE

12260

Gastrointestinal

The gastric lumen is mildly distended with ingesta, despite fasting. The gastric wall and pylorus are normal in thickness with a normal layering pattern. The pyloric outflow tract is patent. A few small intestinal

DATE

2.23.23

segments are distended with chyme, slightly shadowing material, and one to two small hypoechoic bodies. The remaining small intestinal segments are empty. The small intestinal wall is normal in thickness with a normal layering pattern and appropriate mural detail. Discreet masses are not identified. The colonic wall is normal. There is no obvious evidence of an obstructive pattern.

Pancreas

The region of the pancreas is isoechoic relative to surrounding omental fat. No obvious parenchymal abnormalities are observed. There is no evidence of regional inflammation or effusion.

Free Abdomen

The peritoneal cavity is normal. There is no evidence of inflammation or effusion. The abdominal lymph nodes are normal/not visible.

Other

A brief echocardiogram reveals no evidence of pericardial effusion or obvious right atrial/auricular mass.

ULTRASONOGRAPHIC FINDINGS

Primary Findings

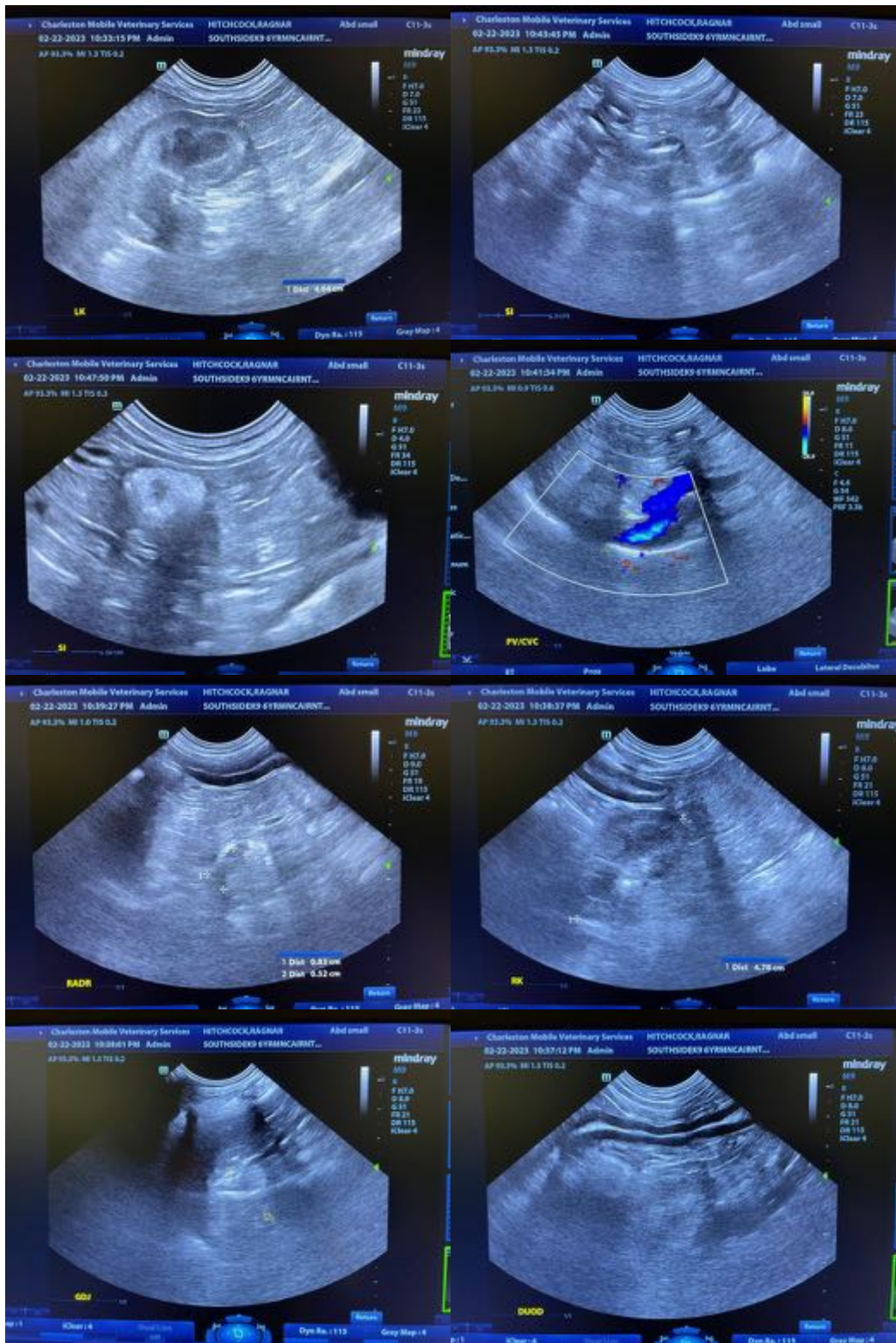
- The presence of ingesta within the gastric lumen despite fasting, could be consistent with delayed gastric emptying. Consider a primary motility disorder or decreased motility secondary to another disease process (i.e., microscopic gastrointestinal disease, underlying metabolic issue, other).
- The faintly shadowing material within the small intestinal lumen, along with the hypoechoic bodies likely represent transient foreign material or ingesta. It appears nonobstructive at this time.

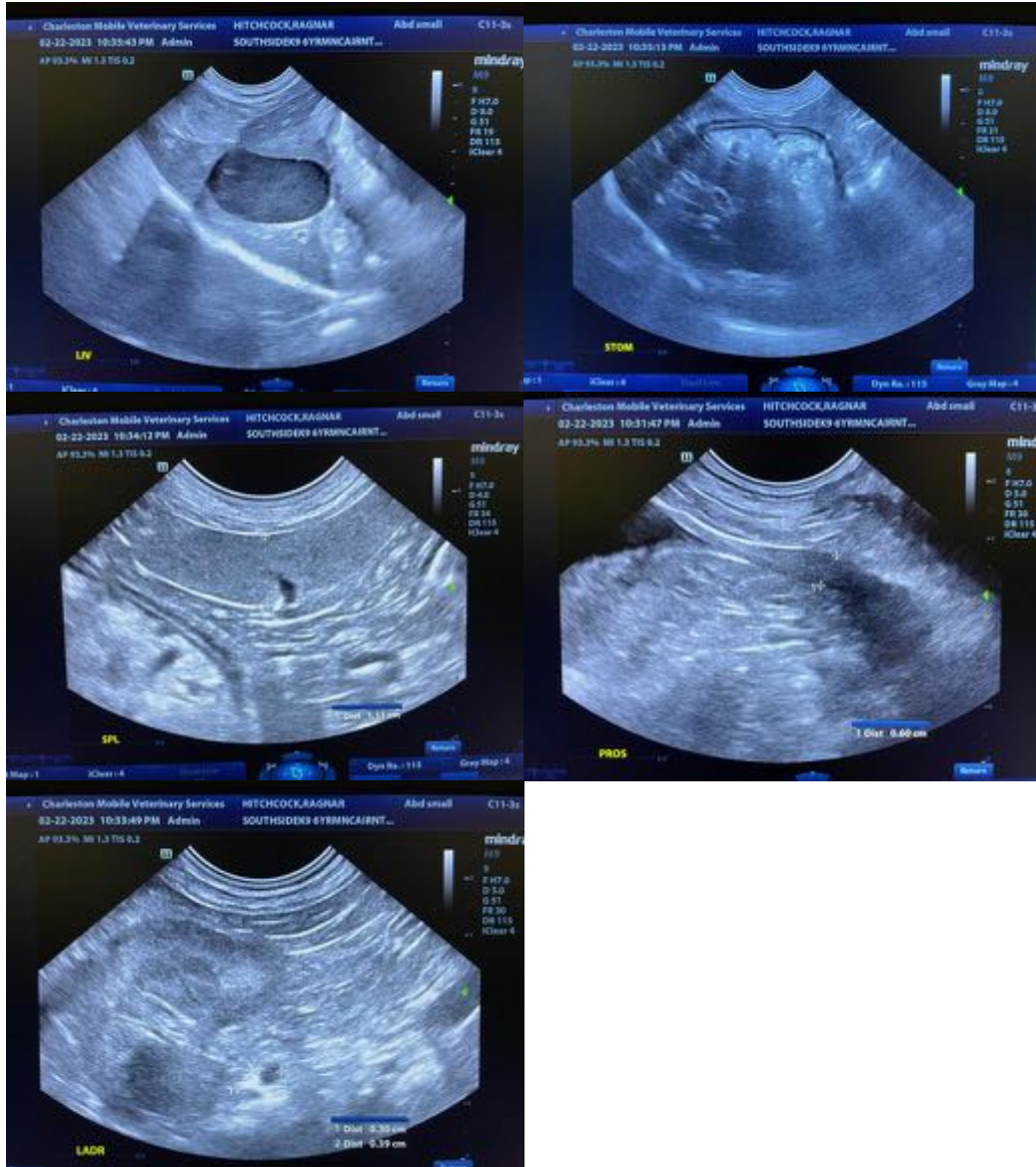
Secondary Findings

- The splenic parenchymal changes are most consistent with a benign process such as lymphoid hyperplasia, extramedullary hematopoiesis, splenitis or antigenic stimulation with a low possibility of infiltrative neoplasia (i.e., lymphoma, mast cell neoplasia).
- The hyperechoic medullary band seen in both kidneys may be a normal variant for this patient or may represent subclinical renal disease.

INTERPRETATION OF THE FINDINGS & FURTHER RECOMMENDATIONS

- Fecal evaluation for ova and Giardia
- GI panel including serum cobalamin and folate, TLI and PLI and a resting cortisol level (send to Texas A&M).
- Consider empirical treatment for a primary motility disorder (i.e., metoclopramide). If the patient does not respond to treatment within 5-7 days of initiating therapy, the drug should be discontinued.
- Also consider initiation of a probiotic.
- Consider a 6-week limited antigen or hydrolyzed protein diet trial.
- Depending on the results of the above diagnostics/therapeutics, an upper GI endoscopy may be warranted.





The information and recommendations provided are based on the images presented by the referring veterinarian/sonographer. No evaluation can be communicated regarding pathology that was not visible in the image/video clips provided.

Thank you for this referral. If the clinical or image interpretation does not parallel your findings or if I can be of any further assistance, please contact me.

Andrea Nicastro, MPH, DVM, Diplomate DACVIM (Small Animal Internal Medicine)
info@SonoPath.com